

Strategies for handling complex pterygium surgery, complications

Spotlighting aggressive pterygia, recurrent pterygia, symblepharon, corneal scars, scleral melts

by Arun C. Gulani, MD

Jacksonville, FL—With a worldwide referral base for complex pterygia and pinguecula complication cases, I have condensed my observations and approach over the past two decades to share in this column.

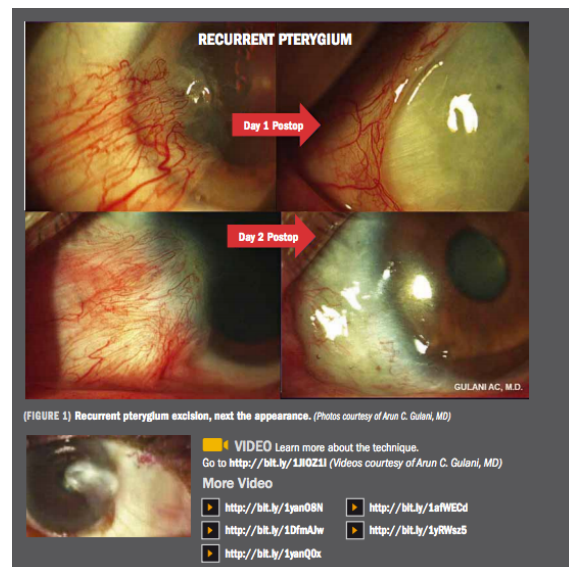
Once again, I must first emphasize that the mindset associated with treating recurrent pterygia and associated complications is the same as when dealing with the virgin pterygial surgery.

Surgeons should not adopt the notion that the previous surgeon did a bad job or that they are now trying to help a patient and therefore aim for a mediocre outcome. Rather, the mindset should be the same as when treating the primary pterygium with the expectation of achieving outstanding cosmetic outcomes on the next postoperative day that will remain stable in the future. Every step should not only correct the problem but also enhance the appearance of the eye and possibly improve vision.

When correcting recurrences and complications arising in pterygia/pinguecula surgery, I have suggested three facets that surgeons must consider: the recurrence and or complications of the lesion itself; the associated conditions such as fornix shortening, corneal and conjunctival scarring, symblepharon, and ischemia or scleral melts; and the predisposing factor for such a recurrence/complication.

Regardless of the expertise of the surgeon who performed the initial surgery, complications can develop that require devising a treatment plan with realistic expectations for the patient but without lowering our own desire to achieve excellence.

I always presume and reiterate to patients that their initial surgeon did the best they could to remove the lesion; the goals of the second surgeon now are to pick up the baton and take it to the end zone by beautifying the eye, correcting



(FIGURE 1) Recurrent pterygium excision, next the appearance. (Photos courtesy of Arun C. Gulani, MD)

VIDEO Learn more about the technique.
Go to <http://bit.ly/1J0Z11> (Videos courtesy of Arun C. Gulani, MD)

More Video

<http://bit.ly/1yan0SN>

<http://bit.ly/1aWEECd>

<http://bit.ly/1DfmAfw>

<http://bit.ly/1yRWsz5>

<http://bit.ly/1yanQ0x>

the comorbidity of associated problems, and enhancing vision.

NEXT: RESECTING RECURRENT LESIONS

To perform minimal dissection, the goal is to identify the bare sclera by careful and gentle cut down through the recurrent scar tissue.

The first surgeon has usually done a nice job of preparing a clear/bare sclera. Once that plane is reached the most difficult part is over. In most cases now the rest of the scariform tissue lifts off like a “plate of armor” from the underlying sclera.

Following this approach there is minimal bleeding. Bleeding usually occurs when surgeons chase the scar tissue from different approaches and cut into it causing multiple planes with a messy and distorted anatomy that further complicates the surgical steps.

In most recurrent cases referred to me, the original pterygium was removed only partially. The surgical steps described in Part 1 of this column can now be followed. These include mitomycin C application and application of Tisseel Glue (Baxter International) along with amniotic graft reconstruction.

FOCUSING ON ASSOCIATED PATHOLOGY

After the mass of the pterygium is removed, the surgeon should consider the anatomy and methods to improve the ocular appearance and address the associated comorbidities.

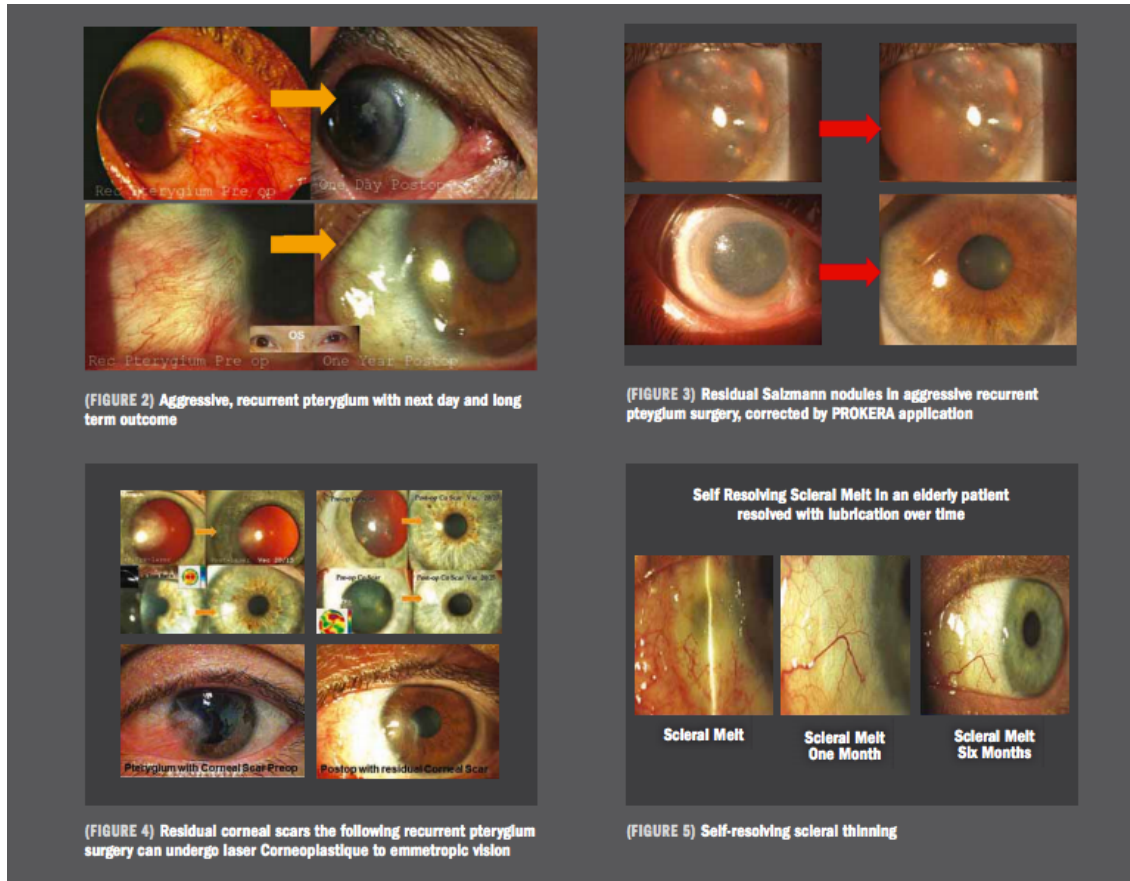
One such adjustment is forming the fornices. This is done by redeepening and relieving the conjunctival scarring and symblepharon, clearing the corneal area using a number 64 blade without cutting in a smooth rapid fashion, and then applying an amniotic graft to reconstruct the fornix by deepening it and arranging the conjunctiva in an elaborate fashion such that it is cosmetically hidden under the lids but is functionally viable.

As described in part 1 of this column, the amniotic membrane can be used to cover the sclera. This can also be multilayered to strengthen the thin sclera. The membrane is attached using Tisseel Glue. The area of the corneal scar is smoothed and application of the amniotic membrane can be extended beyond the limbus onto the cornea for better healing. In many of these cases, I use ProKera (Bio-Tissue) or AmbioDisk (IOP Ophthalmics) on the day after the surgery.

Sclera melts are another possible complication of pterygium surgery; some of these are self-resolving while others require a tissue intervention such as lamellar cornea, conjunctival, or Tenon’s pedicles, and amniotic graft reconstruction. In severe cases, I also use Tutoplast (Tutogen Medical GmbH) with amniotic graft combination to further reconstruct and strengthen the sclera.

NEXT: PREDISPOSING COMORBIDITIES

The Tenon’s pedicle can be used to supply vascularity to a usually ischemic sclera and the lamellar cornea can be used in cases with superficial scleral thinning and glued in place for a cosmetically appealing endpoint.



Granulomas also can occur in some case and can resolve spontaneously with steroids or gentle cautery excision.

In extensive and deeper scleral involvement, I also have used Tutoplast and tried to always keep it the least bulky as possible. While these are salvage cases, the extraocular movement and appearance should be preserved as best as possible.

These cases can look cosmetically appealing the next day after surgery and remain that way for years to come. An anchor suture can be used if needed. Clearing and strengthening are the main objectives, although cosmesis and vision are the primary desires.

Corneal scars can be easily addressed using Laser Corneoplastique principles as explained in previous columns (Decoding Corneal Scars) and the patients can achieve emmetropia.

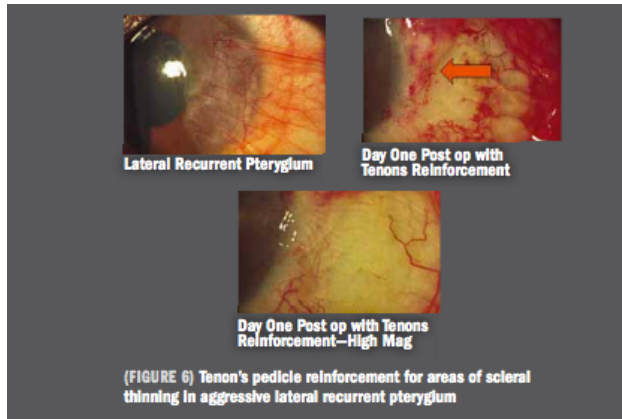
PREDISPOSING COMORBIDITIES

If predisposing conditions such as rheumatoid arthritis, Sjögrens syndrome, dry eye, or collagen vascular diseases are present, we must involve the patient's physician for a systemic workup and management.

In addition, every attempt at surgery raises the chances of a recurrence so we must strive to do it right the first time following the principles of the Iceberg concept.

This minimalistic approach results in surprisingly good results for these patients with its elegant arrangement of tissue. The cosmetic outcomes, high functionality, and improved vision are the final goals of this surgery regardless of the preoperative appearance. Therefore, recurrent pterygia can be addressed in the same fashion but with a slightly different approach and the same mindset as the initial surgeries.

Importantly, numerous patients of mine who have undergone complex pterygial surgery and complication correction have also undergone subsequent laser vision surgery and premium Cataract surgery with excellent visual outcomes.



NEXT: CONCLUSION

Given the unique nature of my practice with a large number of patients referred for cosmetic outcomes, their expectations need to be addressed because doing a mediocre

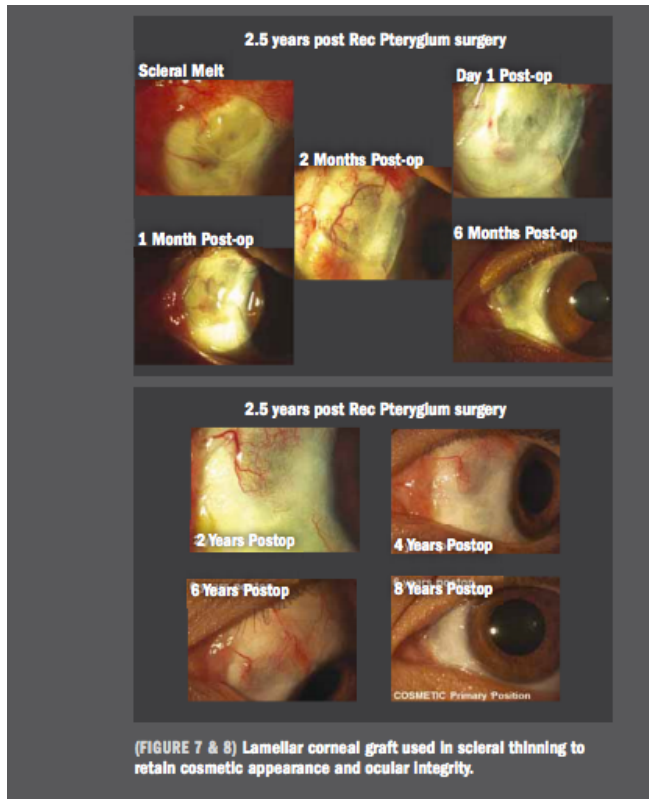
job on a case in which the pterygium/pinguecula was primary and small but with a resultant scar is less tolerable and more agonizing than a recurrence in a complex pterygium case.

This is very similar to present-day premium cataract surgery where patients with 20/60 vision and easily extractable cataracts expect perfection as opposed to patients with 20/400 vision even if the latter may have a mature, hard, and complex cataracts.

This is the price we must pay for our desire to excel for our patients by undertaking this level of commitment as long as the patients are educated about the fact that complications can occur.

Mastering the art of pterygium and pinguecula surgery to treat emerging cases as well as complications and side effects empowers the surgeon to become a full-spectrum ocular surface surgeon who relentlessly follows the goals of raising the bar on ocular surface surgery to cosmetic outcomes along with enhancing vision simultaneously.

In an upcoming “Gloves Off with Gulani” column, I look forward to discussing “Designer Cataract Surgery: Beyond Premium Technology; The Time Is Now.”



References

1. Gulani AC. Sutureless amniotic surgery for pterygium: cosmetic outcomes for ocular surface surgery. *Techniques in Ophthalmology*. 2008;6:41-4.
2. Gulani AC. No-stitch pterygium surgery: next day cosmetic outcomes. *Video Journal of Ophthalmology*. 2009.
3. Gulani AC. Corneoplastique. *Video Journal of Cataract and Refractive Surgery*. 2006;22:3.
4. Gulani A, Gulani A. pterygium surgery: raising ocular surface surgery to cosmetic outcomes. *Mastering corneal surgery: recent advances and current techniques*. Thorofare, NJ: SLACK Incorporated. 2015;25:269-276.
5. Gulani AC. Gulani Iceberg Technique. *Cataract & Refractive Surgery Today Europe*. 2014;9:48-49.
6. Gulani, AC. A cornea-friendly pterygium procedure. *Rev Ophthalmol*. 2012;52-56.
7. Gulani AC. Shaping the future and reshaping the past: the art of vision surgery. Chapter 98. In: Copeland and Afshari's *Principles and Practice of Cornea*. New Delhi, India: Jaypee Brothers Medical Publishers 2013;2: 1252-1273.
8. Gulani AC. Corneoplastique. *Ind J Ophthalmol*. 2014;62:3-11.
9. Gulani, AC. *Competencies in oculoplastics: anatomy, trauma, involutions, and exam preparation*. New Retina MD. 2013;1-2.